

CENTRAL PRESENTATION  
DHAKA MEDICAL COLLEGE HOSPITAL

# A 60-YEAR-OLD WOMAN WITH BREATHLESSNESS

---

DR. SADIA NOWRIN PROMY  
FCPS P-2 TRAINEE (CMT)  
MEDICINE UNIT 4

# PARTICULARS OF THE PATIENT

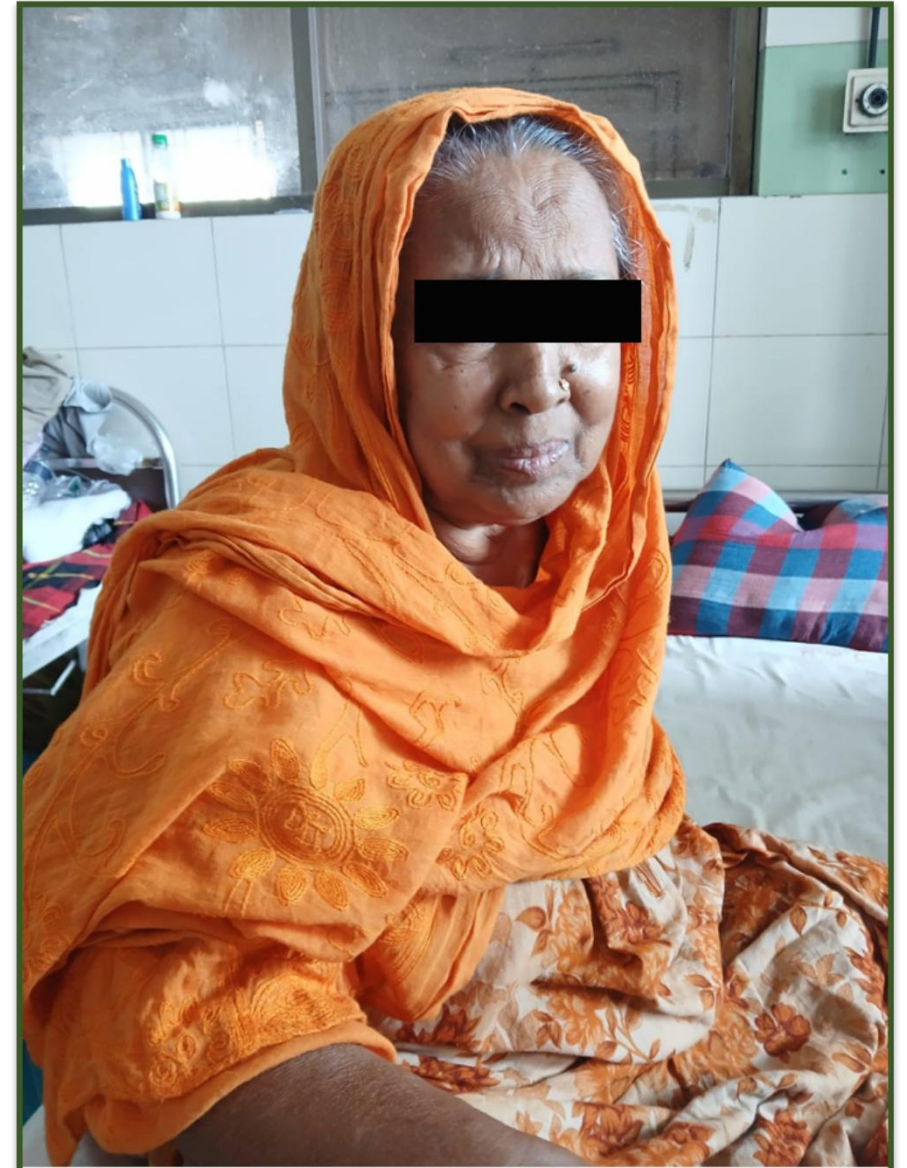---

- Name : Mrs X
- Age : 60 Years
- Sex : Female
- Occupation : Housewife
- Marital Status: Married
- Address : Madaripur
- Date Of Admission: 17 Aug 2024
- Date Of Examination: 17 Aug 2024

# THE PRESENTING COMPLAINTS

---

- Breathlessness for 3 months
- Fever for 2 months
- Cough for 15 days



Picture taken with consent of the patient

# THE PATIENT HISTORY

# HISTORY OF PRESENT ILLNESS

---

Mrs. X was reasonably well 4 years back. Then she developed breathlessness that:

- Initially appeared only on moderate to severe exertion
- Progressively increasing for the last 3 months
- Became worse with mild exertion
- Now grade 3 on mMRC scale

# HISTORY OF PRESENT ILLNESS

---

Her breathlessness was not associated with:

- Seasonal or diurnal variation
- Aggravation on dust, fume or cold exposure
- Worsening when lying flat
- Waking up from sleep
- Chest pain

# HISTORY OF PRESENT ILLNESS

---

She also complained of cough which:

- Was non-productive and recurrent in the past 4 years
- Had no seasonal or diurnal variation
- Was not associated with expectoration of blood
- Used to aggravate & became productive for the last 15 days

# HISTORY OF PRESENT ILLNESS

---

She had intermittent fever for the last 2 months:

- Highest recorded temperature was 101° F
- Subsided with antipyretics
- No evening rise of temperature or night sweats

# HISTORY OF PRESENT ILLNESS

---

- She has been diabetic & hypertensive for the past 7 years, well controlled with medications
- Diagnosed with CKD, 4 years ago
- Normal bladder and bowel habits

# HISTORY OF PRESENT ILLNESS

---

There were no history of:

- Contact with tuberculosis patients
- Documented COVID-19 infection
- Joint swelling or pain
- Skin tightening, rash
  
- Weight loss
- Oral ulcer
- Difficulty in deglutition
- Dry eyes or mouth

# HISTORY OF PRESENT ILLNESS

---

- On query, she gave history of contact with poultry (ducks and chickens) at her home
- Also reported some contact with pigeons for 8 years, as her neighbor breeds those

# HISTORY OF PAST ILLNESS

---

- No significant past medical history.

# DRUG HISTORY

---

- Linagliptin 5 mg OD
- Regular Insulin 6 units before meal TDS
- Olmesartan 20mg OD
- Atorvastatin 20mg OD
- Salmeterol/Fluticasone Combination Inhaler  
BD

# FAMILY HISTORY

---

- No family history of consanguinity
- No history of similar illness in her family
- Married for 30 years with 4 children

# PERSONAL HISTORY

---

- Does not smoke or use any tobacco products
- Occasionally chewed betel-nut

# OBSTETRIC & GYNAECOLOGICAL HISTORY

---

- Menopausal for last 12 years
- No history of pregnancy loss
- Pregnancies were uneventful

# SOCIOECONOMIC HISTORY

---

- Comes from a middle-class family
- Lives in a pacca house
- Drinks arsenic free water
- Has been using biomass fuel for last 8 years

# IMMUNIZATION HISTORY

---

- Vaccinated against
  - BCG
  - Tetanus
  - Small pox
  - Covid-19 (3 doses)
  - No history of influenza or pneumococcal vaccination

# EXAMINATION

# GENERAL EXAMINATION

---

- Appearance : Ill-looking,  
breathless

---

- BMI : 29 Kg/m<sup>2</sup>

---

- Nutrition : Average

---

- Co- : Co-operative  
operation

---

- Decubitus : On choice

---

- Anemia : Mild

- Oedema : Present

---

- Jaundice : Absent

---

- Cyanosis : Absent

---

- Clubbing : Absent

---

- Koilonychia : Absent

---

- Leukonychia : Absent

# GENERAL EXAMINATION

---

- Dehydration : Absent

---

- JVP : Not raised

---

- Pulse : 96 BPM

---

- BP : 100/80 mmHg, no postural drop

---

- Temperature : 98° F

---

- Resp Rate : 22 breaths/min

# GENERAL EXAMINATION

---

- **O<sub>2</sub> Saturation** : 97% at rest, 88% after mild exertion

---

- Lymph Node : Not enlarged

---

- Thyroid Gland : Not enlarged

---

- Bony Tenderness : Absent

---

- Hair distribution : Normal

---

- Pigmentation : Absent

---

- **Bed-side urine** : Protein (+), Sugar (++)

# RESPIRATORY SYSTEM EXAMINATION

---

- Respiratory rate: 22 breaths/min
- Inspection:
  - Chest movement restricted symmetrically
  - No scar mark, visible deformity, visible impulse or engorged vein
  - No suprasternal, supraclavicular or intercostal recession

# RESPIRATORY SYSTEM EXAMINATION

---

- Palpation
  - Trachea: Centrally placed
  - Apex: Normal in position
  - Chest expansion: Symmetrically reduced (4 cm)
  - Vocal fremitus: Normal

# RESPIRATORY SYSTEM EXAMINATION

---

- Percussion :
  - Resonant bilaterally
- Auscultation:
  - Breath sound: Vesicular
  - Added sound: End inspiratory crepitations all over the chest (bilateral); not altered with cough
  - Vocal resonance: Normal

# PRECORDIUM EXAMINATION

---

- Inspection:
  - No visible deformities/ pulsation/ scar marks
- Palpation:
  - Apex beat located at the left 5th intercostal space, 9cm from midline, normal in character
  - P<sub>2</sub> not palpable
  - No thrill/heave
- Auscultation :
  - 1st & 2nd heart sounds normal & heard in all cardiac areas. No added sounds

# NERVOUS SYSTEM EXAMINATION

---

- Higher Psychic Function:
  - Oriented in time, place and person
  - Memory: Intact
  - Speech: Normal
  - Language: Normal
- Cranial Nerves: Intact
- Fundus: Pre-proliferative retinopathy
- Signs of meningeal irritation: Absent

# NERVOUS SYSTEM EXAMINATION

---

- Motor functions:
  - Upper limb :
    - Bulk: Normal (B/L)
    - Tone : Normal (B/L)
    - Power : 4/5 (B/L)
    - Reflexes: Diminished (B/L)
- Co-ordination: Intact
- Lower limb
  - Bulk: Normal (B/L)
  - Tone : Normal (B/L),

# NERVOUS SYSTEM EXAMINATION

---

- Sensory
  - Upper limb : Normal
  - Lower limb : All sensory modalities diminished up to knee joint

# OTHER SYSTEMIC EXAMINATION

Revealed no abnormalities

# SALIENT FEATURES

---

Mrs X, 60-year-old housewife, a known case of hypertension and diabetes (7 years) with CKD(Stage 4), got admitted into this hospital with a 4-year history of:

Progressive exertional breathlessness & persistent dry cough. Both the symptoms aggravated significantly in recent past; breathlessness for 3 months & cough over the last 15 days, with purulent expectoration. She denied any chest pain, orthopnoea or PND, neither she had any complaints relating to connective tissue diseases; but admitted having contact with poultry & pigeon from her next-door neighbor.

She also had intermittent fever for the last 2 months, but no significant contact with TB patient.

# SALIENT FEATURES

---

On general examination, she looked breathless, had mild anaemia & oedema; marked O<sub>2</sub> desaturation on mild exertion. Bed-side urine was positive for protein and sugar.


Chest examination revealed symmetrical restriction of chest movement & a bilateral end inspiratory crepitation- unaltered with cough, all over the lungs fields.

Neurological examination was consistent with distal sensory-motor neuropathy in the lower limbs.

Fundoscopy showed pre-proliferative retinopathy.

# PROBLEM LIST

# PROBLEM LIST FROM AUDIENCE

A large, empty rectangular box with a thin black border, positioned centrally below the title. It is intended for the user to list the problems identified by the audience.

Progressive  
Shortness of  
Breath

Contact With Birds

Dry Cough


Fever

**60-YEAR-OLD  
FEMALE WITH  
DM, HTN, CKD**

Inspiratory  
Crepitation

Diabetic  
Complications

WHAT COULD OUR DIAGNOSIS BE?



# PROVISIONAL DIAGNOSIS

DPLD (? Hypersensitivity pneumonitis) & HTN & DM with Complications

# DIFFERENTIAL DIAGNOSIS

- Other DPLD (Idiopathic pulmonary fibrosis & others)
- Sarcoidosis
- Vasculitis

& HTN & DM with CKD

# INVESTIGATIONS

## COMPLETE BLOOD COUNT

	18.08.24	28.08.24
Hb	9 g/dl	8 g/dl
WBC	17,380/cumm	11,650/cumm
Neutrophil	83%	82.2%
Lymphocyte	8%	9.5%
Eosinophil	4%	4.3%
Platelet	4,57,000/cumm	3,36,000/cumm

## PERIPHERAL BLOOD FILM

RBC: Normocytic normochromic

WBC: Increased in number and predominance of neutrophils

Platelets: Normal

**Comment:** Normocytic anaemia with neutrophilic leucocytosis

## BIOCHEMISTRY

	<b>18.8.24</b>	<b>28.8.24</b>
S. creatinine	<b>4.61 mg/dl</b>	<b>2.13 mg/dl</b>
Na <sup>+</sup>	140 mmol/L	140 mmol/L
K <sup>+</sup>	4.9 mmol/L	3.1 mmol/L
Cl <sup>-</sup>	111 mmol/L	106 mmol/L
Blood urea	<b>54 mg/dl</b>	

## BIOCHEMISTRY

	<b>18.8.24</b>
S. Albumin	<b>2.9 g/dL</b>
S. Total calcium	<b>6.9 mg/dl</b> (Corrected Ca: <b>7.8 mg/dL</b> )
Inorganic phosphate	<b>9.74 mg/dl</b>
Parathyroid hormone	<b>245.6 pg/ml</b>
Random blood sugar	4.8 mmol/L
HbA <sub>1c</sub>	<b>7.2%</b>

## URINE RME

	<b>18.08.24</b>
Albumin	+++
Sugar	+
Epithelial cells	0-4/HPF
Pus cells	<b>15-20/HPF</b>

## ALBUMIN CREATININE RATIO

	<b>28.08.24</b>
Microalbumin	<b>2456 mg/L</b>
ACR	<b>4093 mg/g</b>

## SPUTUM MICROSCOPY

	<b>18.08.24</b>
Epithelial cell	0-2 /HPF
Pus cell	0-1 /HPF
Gram stain	A few Gram positive diplococci (pneumococci)

## MICROBIOLOGY

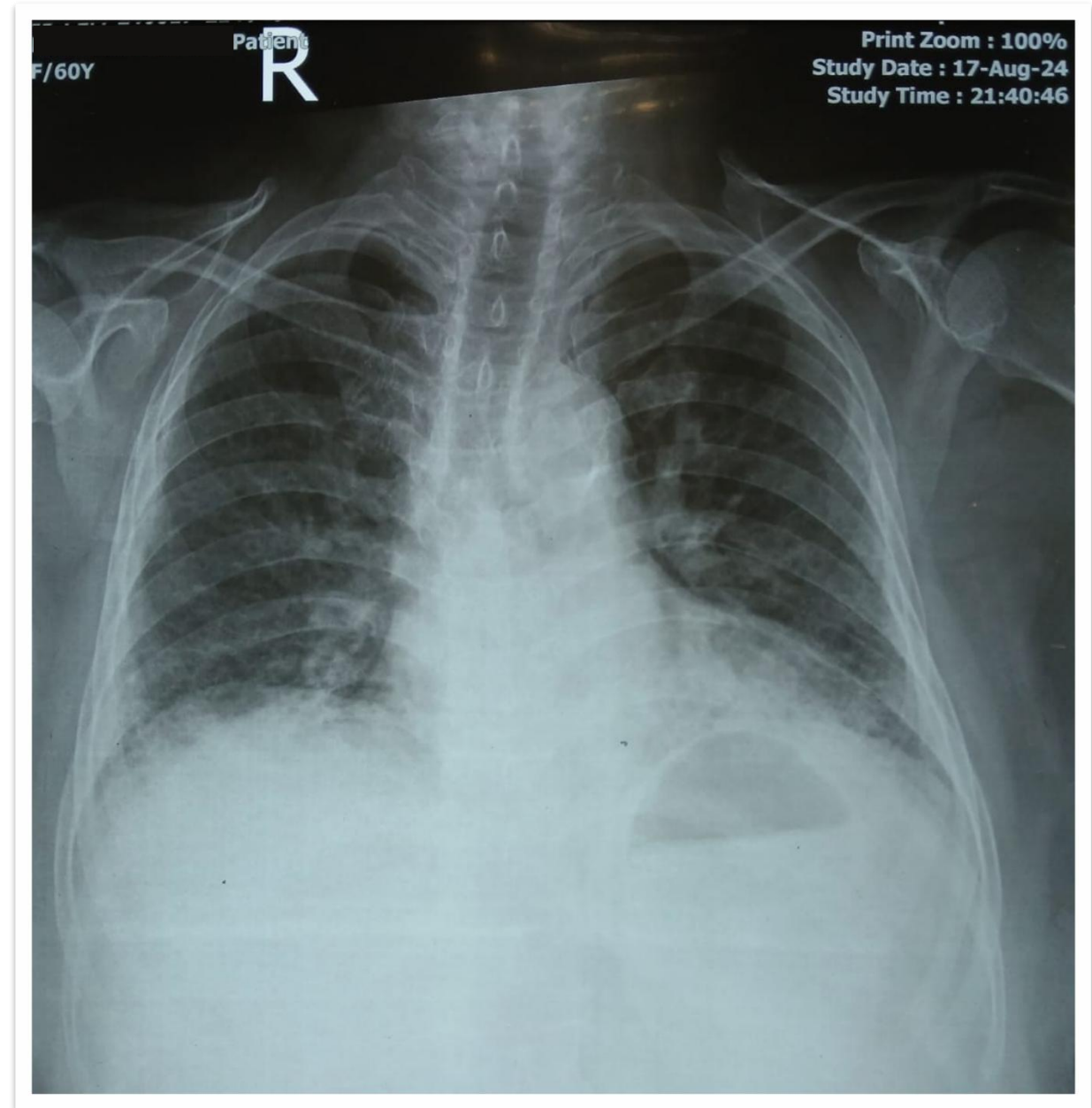
Blood C/S	No growth
Urine C/S	No growth
Sputum C/S	No growth

## AUTOIMMUNE SEROLOGIES

ANA	Negative
cANCA	Negative
pANCA	Negative
RA Factor	Negative
ACE Levels	24 µgrams/L

## CHEST X-RAY

- Lung volume reduction
- Inhomogeneous opacity with reticular shadowing in bilateral lower zones, peripherally



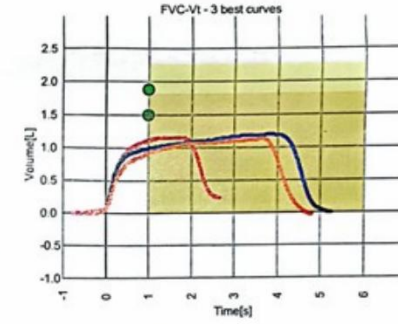
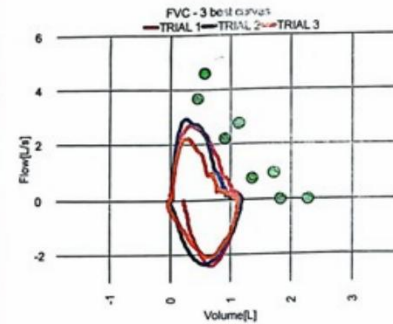
## SPIROMETRY

- FEV<sub>1</sub> : 59%
- FVC: 51%
- FEV<sub>1</sub> /FVC: 117%
- Interpretation: **Moderate to severe restriction**

First name ANOWARA  
Last name BEGUM  
Id D 3459076  
Age 60  
Sex Female

Time Stamp 01.09.2024 07:25:39  
Height 146.00 cm  
Weight 62.00 kg  
Ethnic Group Caucasian  
Smoker No  
Prediction method Knudson

REF-DMCH



	Unit	Predicted	%PRED	BEST	TRIAL 1	TRIAL 2	TRIAL 3
FVC	L	2.27	51%	1.15	1.15	1.19	1.13
FEV1	L	1.88	59%	1.11	1.11	0.99	0.91
FEV1%FVC	%	82.73	117%	96.52	96.52	83.19	80.53
FET	s	0.00	0%	1.32	1.32	3.86	3.64
FEF25	L/s	4.62	58%	2.68	2.68	2.89	2.21
FEF50	L/s	2.76	86%	2.38	2.38	2.21	1.33
FEF75	L/s	0.94	91%	0.86	0.86	0.44	0.30
FEV6	L	0.00	0%	1.15	1.15	1.19	1.13
PEF	L/s	4.89	55%	2.71	2.71	2.94	2.22
PIF	L/s	4.89	49%	2.40	2.40	2.36	2.09
FIF25	L/s	0.00	0%	0.00	0.00	1.78	1.29
FIF50	L/s	0.00	0%	1.78	1.78	2.36	2.05
FIF75	L/s	0.00	0%	2.40	2.40	1.72	1.65
MMEF2550	L/s	0.00	0%	2.62	2.62	2.71	1.88

**Quality control**

ATS/ERS quality criteria not met! Need 2 more good blows.

**Automatic interpretation**

Moderate Severe Restriction

ASTHMA-YES, DRUGS-YES

**Doctor's Note**

*Pl. Correlate Clinically*

*2.2.28*

**Dr. Mahbulul Islam**  
MBBS DTCD (DU) MSc FCCP  
Senior Consultant Respiratory Medicine  
Regular Diagnostic Center (Respiratory Medicine) Dhaka

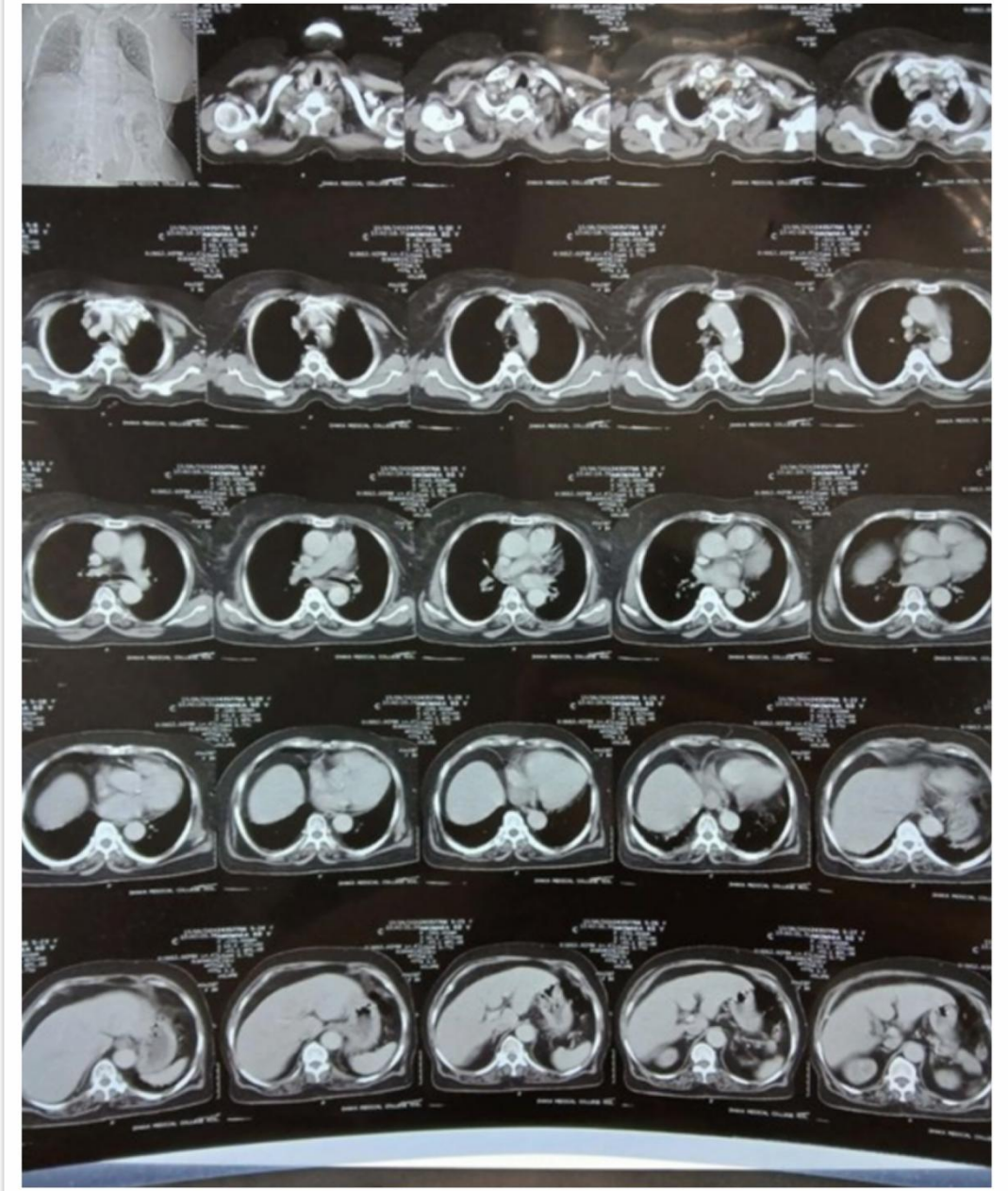
## CT SCAN OF CHEST

- Bilateral subpleural ground-glass opacities with subpleural streaks present in some section suggestive of post-covid state.
- D/D: Idiopathic Pulmonary Fibrosis



## CT SCAN OF CHEST

- Bilateral subpleural ground-glass opacities with subpleural streaks present in some section suggestive of post-covid state.
- D/D: Idiopathic Pulmonary Fibrosis



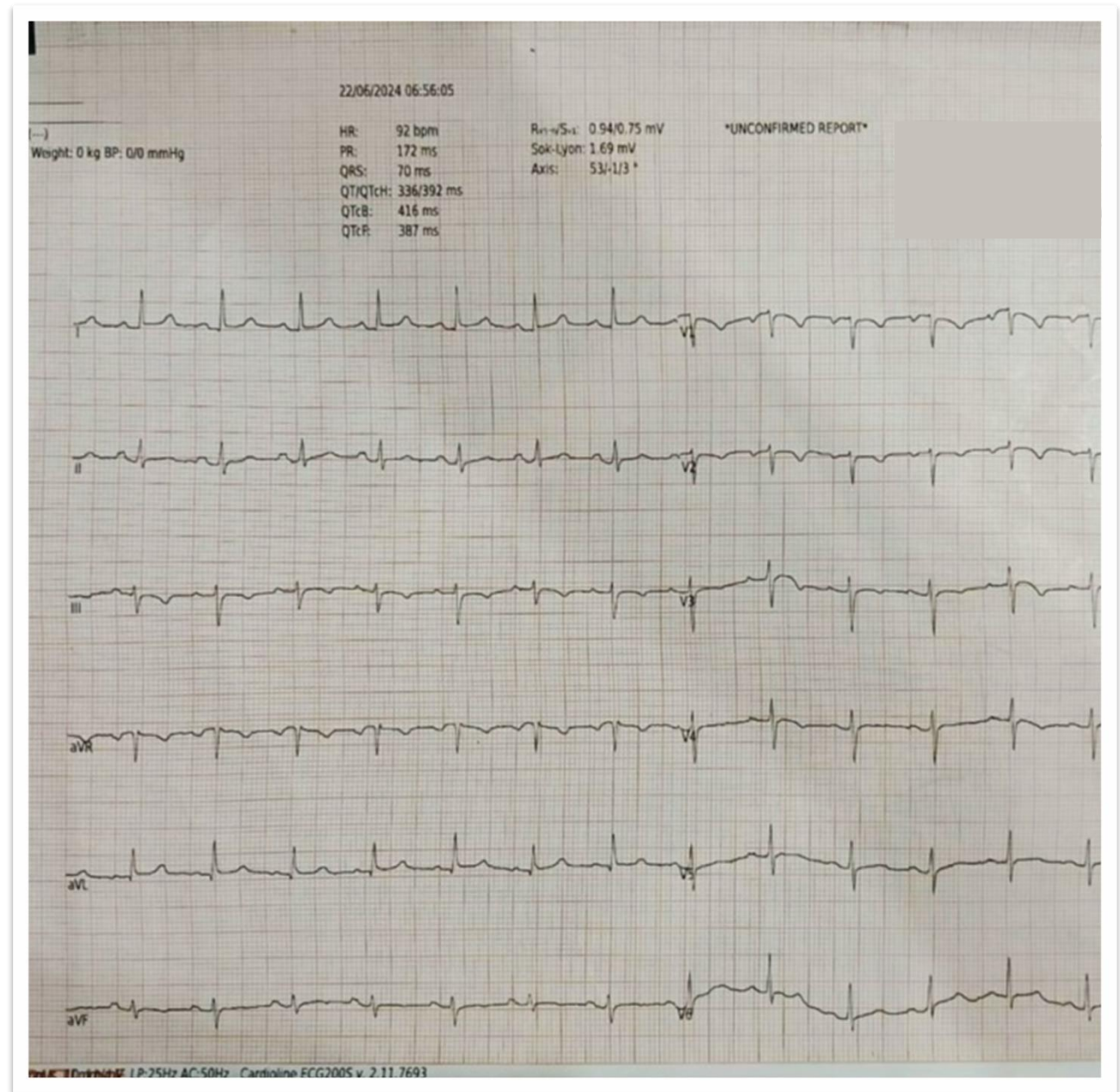
## CT SCAN OF CHEST

- Bilateral subpleural ground-glass opacities with subpleural streaks present in some section suggestive of post-covid state.
- D/D: Idiopathic Pulmonary Fibrosis





## ECG

- Sinus rhythm
- Left axis deviation



# ECHOCARDIOGRAPHY

- No regional wall motion abnormality
- Normal LV systolic function (EF: 60%)
- Diastolic relaxation abnormality
- Aortic sclerosis
- Trivial TR
- PASP 34 mmHg

			
Patient Name :	MRS. ANWARA BEGUM	Report No :	300931399
UHID / IP NO	300740016 (146205)	Delivery Date:	16/06/2024 11:34AM
Age/Gender :	60 Y/F	Film No:	
Contact No :	01987374294	Invoice No :	OPYD/24/290093
Referred By :	DHAKA MEDICAL COLLEGE HOSPITAL	Invoice Date :	16/06/2024 10:15AM

**ECHO CARDIOGRAPHY 2D**

**Interpretation Summary:**

- Normal chamber dimensions.
- No regional wall motion abnormality.
- Normal LV systolic function (EF: 60%).
- Diastolic relaxation abnormality.
- Aortic sclerosis.
- Trivial TR (PASP: 34 mmHg) with mild pulmonary hypertension.
- No thrombus/vegetation/ pericardial effusion seen.

**2D Study:**

Situs : Solitus  
 RA : Normal  
 RV : Normal free wall motion.  
 LA : Normal. LAA is clear.  
 LV : Cavity normal. No RWMA. No thrombus.  
 Mitral Valve : Normal motion pattern. No SAM / Prolapse.  
 Aortic Valve : All three aortic cusps are thickened with mild calcification.  
 Tricuspid Valve : Normal in morphology & motion.  
 Pulmonary Valve : Hypertensive motion.  
 IVS : Intact  
 IAS : Intact  
 Pericardium : No pericardial effusion or disease seen.  
 SVC/IVC : Normal  
 Pulm. Artery : Normal  
 Pulm. Veins : Normal


**M-Mode Measurements:**

LV Diastole	: 4.7 cm.	LV : Systole	: 3.2 cm.
IVS(d)	: 1.0 cm	IVS (s)	: 1.3 cm.
LVPW (d)	: 1.0 cm	LVPW (s)	: 1.4 cm.
LVEF	: 60 %	FS	: 32 %
Left Atrium	: 3.5 cm	LA /Ao	: 1.02
Aorta	: 3.4 cm	ACS	: 0.9 cm

**Comment:**

- No regional wall motion abnormality.
- Normal LV systolic function (EF: 60%).
- Diastolic relaxation abnormality.
- Aortic sclerosis.
- Mild pulmonary hypertension.

Prepared By: Mohammad Sagor Hossain

  
**DR MD ROBIUL ISLAM**  
 MBBS, D-CARD (BSMMU)  
 Consultant in Cardiology  
 Labaid Cardiac Hospital

House 1, Road 4, Dhaka

## USG of W/A

- Bilateral renal parenchymal disease

THANK YOU FOR REFERRING THE PATIENT

### USG OF WHOLE ABDOMEN

- Liver** : Liver is normal in size. Parenchymal echogenicity appears homogeneous. Parenchymal echogenicity is not increased. No focal lesion is seen. Portal vein caliber and hepatic veins channels are within normal limit.
- Gall bladder** : Gall bladder is normal in size, shape with normal wall thickness. Lumen is clear.
- Biliary channels** : Intra & extrahepatic biliary trees are not dilated. CBD is normal in caliber.
- Pancreas** : Normal in size, shape in outline with uniform echotexture. MPD is not dilated.
- Spleen** : Normal in size with uniform echotexture. No focal lesion is seen.
- Kidneys** : Normal in size, shape and position. Cortical echogenicity is ~~normal~~ increased. Cortico-medullary differentiation is maintained in both kidneys. Pelvicalyceal systems are not dilated on both kidneys. No calculus seen.
- Urinary bladder** : Well filled, Wall thickness is within normal limit and regular in outline. No intravesical lesion is noted.
- Prostate/Uterus** : Atrophied

Comment : Bilateral renal parenchymal diseases.

# FINAL DIAGNOSIS

Idiopathic Pulmonary Fibrosis & HTN & DM & Urosepsis with AKI  
on CKD

## MANAGEMENT

- Cap. Doxycycline 100mg BD for 7 days
- Tab. Clarithromycin 500mg BD for 7 days
- Cap. Nintedanib 100mg BD continue
- Tab. Telmisartan 40mg OD continue
- Tab. Linagliptin 5mg OD continue
- Tab. Rosuvastatin 5mg OD continue
- Cap. Calcitriol 0.25 mcg OD 1 month

The patient was managed accordingly and discharged home after improvement

Still the journey goes on.....

# AN UNWANTED DEVELOPMENT

Patient returned one month later with worsening breathlessness and delirium,  
deteriorated renal function & signs of fluid overload

Of significant note: Urine R/M/E revealed proteinuria & significant hematuria  
No growth in Urine C/S

This time around, what else should we consider?

## BIOCHEMISTRY

	<b>28.8.24</b>	<b>01.10.24</b>
S. creatinine	2.13 mg/dl	<b>4.7 mg/dl</b>
Na <sup>+</sup>	140 mmol/L	<b>149 mmol/L</b>
K <sup>+</sup>	3.1 mmol/L	<b>6.1 mmol/L</b>
Cl <sup>-</sup>	106 mmol/L	<b>106 mmol/L</b>
Urea	54 mg/dL (18.8.24)	<b>125 mg/dL</b>

# AUTOIMMUNE SEROLOGIES

	Result	Normal Value
cANCA	4.35 U/ml	<5 U/ml
pANCA	<b>25.12 U/ml</b>	<5 U/ml
Anti-CCP	5.08	<17 U/ml

Test	Result	Unit	Bio. Ref. Interval
p ANCA	<b>25.12</b>	U/ml	<5 : Negative >=5 : Positive
c ANCA	4.35	U/ml	<5 : Negative >=5 : Positive
Anti-Cyclic Citrullinated Peptide (Anti-CCP)	5.08	U/ml	<17.0 U/mL=Negative >17.0 U/mL=Positive
Method : Chemiluminescence Immunoassay ELISA			

# AUTOIMMUNE SEROLOGIES

Test	Result	Normal Value
pANCA (Anti-MPO) antibody	<b>&gt;100 U/ml</b>	<5 U/ml

<b>Sample :</b> Blood		<b>Lab. No. :</b> 12530784	
<b>Tests :</b> p-ANCA (Anti MPO) antibody			
Test	Concentration/AI	Opinion	Reference Value
p-ANCA (Anti MPO ) antibody	<b>&gt;100.0 U/ml</b>	<b>Positive</b>	< 5.0 U/ml : Negative > 5.0 U/ml : Positive
Method: Alegria (Automated ELISA)			

# FINAL DIAGNOSIS

Post COVID-19 ANCA-associated vasculitis [Microscopic polyangiitis(MPA)]  
with DPLD & HTN & DM with complications with AKI on CKD

There have been documented cases of ANCA associated vasculitis developing in COVID-19 patients



## ANCA-associated vasculitis after COVID-19

Tugba Izci Duran<sup>1</sup> · Ercan Turkmen<sup>2</sup> · Melda Dilek<sup>2</sup> · Hayriye Sayarlioglu<sup>2</sup> · Nurol Arik<sup>2</sup>

Received: 6 April 2021 / Accepted: 3 June 2021 / Published online: 7 June 2021

© The Author(s), under exclusive licence to Springer-Verlag GmbH Germany, part of Springer Nature 2021

### Abstract

Antineutrophil cytoplasmic antibody (ANCA)-associated vasculitis (AAV) are systemic autoimmune diseases that may lead to renal failure due to the infiltration of mononuclear cells and the destruction of small- and medium-sized blood vessels. It has been shown that severe acute respiratory syndrome coronavirus 2 (SARS-CoV-2) may trigger the presentation or exacerbation of autoimmune diseases. Crescentic glomerulonephritis (GN) has rarely been reported in patients with Coronavirus disease-2019 (COVID-19). We present rare two cases with AAV after a recent diagnosis of COVID-19. The first case was 26-year-old male patient, who was presented with acute kidney injury after COVID-19. Serum creatinine increased and active urine sediment was seen. Serological evaluation showed anti-myeloperoxidase antibody was at a level of 80.6 U/mL. Kidney biopsy showed necrotizing GN with cellular crescents. Methylprednisolone, cyclophosphamide and plasma exchange were administered. He was discharged with hemodialysis. Second case was a 36-year-old female who was hospitalized because of fever, cough and dyspnea. After she was diagnosed with COVID-19, she had total hearing loss, with cavitary lesions on bilateral lung parenchyma and an acute kidney injury. Serological evaluation showed an elevated anti-proteinase-3 with a level of 1:32. Kidney biopsy showed necrotizing GN with cellular crescents. Renal function improved after methylprednisolone and cyclophosphamide treatment. With a systematic review of the literature, we found four cases of new-onset AAV due to COVID-19. Herein, we discuss two cases and provide a literature review on cases of new-onset pauci-immune GN after COVID-19 infection.

**Keywords** Anti-neutrophil cytoplasmic antibody-associated vasculitis/diagnosis\* · COVID-19 · Glomerulonephritis/pathology\* · SARS-CoV-2\*

### Introduction

Antineutrophil cytoplasmic autoantibody (ANCA)-associated vasculitis (AAV) is a disorder that affects predominantly small- and medium-sized arteries and has similar features on kidney histology [e.g., a focal necrotizing, often crescentic, pauci-immune glomerulonephritis (GN)] [1]. The events leading to the initiation of AAV are not well understood. Some factors are involved in the pathogenesis of the disease by triggering autoimmunity due to genetic factors, infectious agents, various specific drugs, environmental exposures and other factors [2–5]. Coronavirus disease-19 (COVID-19), a newly occurred respiratory disease caused by severe acute respiratory syndrome coronavirus-2 (SARS-CoV-2), was first detected in China, in December 2019, and has caused deaths of more than 2.5 million people thus far. As the COVID-19 outbreak continues to expand, many aspects of this disease are being defined and described in detail. Acute kidney injury (AKI) has also been

✉ Tugba Izci Duran  
drtugbaizcidaran@gmail.com  
Ercan Turkmen  
ercan.turkmen1907@gmail.com  
Melda Dilek  
dilekmelda@yahoo.com  
Hayriye Sayarlioglu  
hayriyesayarlioglu@yahoo.com  
Nurol Arik  
nurarik@superonline.com

<sup>1</sup> Division of Rheumatology, Department of Internal Medicine, Ondokuz Mayıs University Medical Faculty, Korfez Mahallesi, 55270 Atakum/Samsun, Turkey

<sup>2</sup> Division of Nephrology, Department of Internal Medicine, Ondokuz Mayıs University Medical Faculty, Korfez Mahallesi, 55270 Atakum/Samsun, Turkey



## ANCA-associated vasculitis after COVID-19

Tugba Izci Duran<sup>1</sup> · Ercan Turkmen<sup>2</sup> · Melda Dilek<sup>2</sup> · Hayriye Sayarlioglu<sup>2</sup> · Nuro! Arik<sup>2</sup>

Received: 6 April 2021 / Accepted: 3 June 2021 / Published online: 7 June 2021

© The Author(s), under exclusive licence to Springer-Verlag GmbH Germany, part of Springer Nature 2021

### Abstract

Antineutrophil cytoplasmic antibody (ANCA)-associated vasculitis (AAV) are systemic autoimmune diseases that may lead to renal failure due to the infiltration of mononuclear cells and the destruction of small- and medium-sized blood vessels. It has been shown that severe acute respiratory syndrome coronavirus 2 (SARS-CoV-2) may trigger the presentation or exacerbation of autoimmune diseases. Crescentic glomerulonephritis (GN) has rarely been reported in patients with Coronavirus disease-2019 (COVID-19). We present rare two cases with AAV after a recent diagnosis of COVID-19. The first case was 26-year-old male patient, who was presented with acute kidney injury after COVID-19. Serum creatinine increased and active urine sediment was seen. Serological evaluation showed anti-myeloperoxidase antibody was at a level of 80.6 U/mL. Kidney biopsy showed necrotizing GN with cellular crescents. Methylprednisolone, cyclophosphamide and plasma exchange were administered. He was discharged with hemodialysis. Second case was a 36-year-old female who was hospitalized because of fever, cough and dyspnea. After she was diagnosed with COVID-19, she had total hearing loss, with cavitory lesions on bilateral lung parenchyma and an acute kidney injury. Serological evaluation showed an elevated anti-proteinase-3 with a level of 1:32. Kidney biopsy showed necrotizing GN with cellular crescents. Renal function improved after methylprednisolone and cyclophosphamide treatment. With a systematic review of the literature, we found four cases of new-onset AAV due to COVID-19. Herein, we discuss two cases and provide a literature review on cases of new-onset pauci-immune GN after COVID-19 infection.

## 2022 ACR/EULAR classification criteria for MPA

Apply only after a Dx. Of MVV/SVV is made Vasculitis mimics should be excluded

### CLINICAL CRITERIA

---

Nasal involvement, bloody nasal discharge, ulcer, crusting congestion, blockade, septal defect/perforation **-3**

---

### LABORATORY IMAGING AND BIOPSY CRITERIA

---

Positive p-ANCA/Anti- MPO **+6**

---

Fibrosis/ILD on CXR **+3**

---

Pauci-immune GN(biopsy) **+3**

---

Positive c-ANCA/(Anti- PR3) **-1**

---

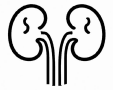Blood eosinophil  $\geq 1 \times 10^9 / L$  **-4**

---

**A SCORE OF  $\geq 5$  POINTS TO CLASSIFY AS MPA**

# TAKE HOME MESSAGE

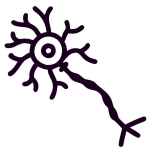
WHEN “DPLD” IS ENCOUNTERED, LOOK FOR:



RENAL INVOLVEMENT(?GN)



CUTANEOUS VASCULITIS



NEUROPATHY (PN, MNM)



CONSTITUTIONAL FEATURE



CONNECTIVE TISSUE DISEASES

# ACKNOWLEDGEMENTS

---

- Department of Respiratory Medicine, DMCH
- Department of Radiology & Imaging, DMCH
- Department of Laboratory Medicine, DMCH
- Department of Microbiology, DMC

THANK YOU ALL